



ELSEVIER

Contents lists available at ScienceDirect

EClinicalMedicine

journal homepage: <https://www.journals.elsevier.com/eclinicalmedicine>

COVID-19 in 7780 pediatric patients: A systematic review

Ansel Hoang^a, Kevin Chorath^{a,†}, Axel Moreira^b, Mary Evans^a, Finn Burmeister-Morton^a,
Fiona Burmeister^a, Rija Naqvi^a, Matthew Petershach^a, Alvaro Moreira^{a,*}

^a Department of Pediatrics, University of Texas Health Science Center San Antonio, San Antonio, Texas, USA

^b Department of Pediatrics, Texas Children's Hospital, Houston, Texas, USA

ARTICLE INFO

Article History:

Received 13 May 2020

Revised 5 June 2020

Accepted 9 June 2020

Available online xxx

ABSTRACT

Background: Studies summarizing the clinical picture of COVID-19 in children are lacking. This review characterizes clinical symptoms, laboratory, and imaging findings, as well as therapies provided to confirmed pediatric cases of COVID-19.

Methods: Adhering to PRISMA guidelines, we searched four medical databases (PubMed, LitCovid, Scopus, WHO COVID-19 database) between December 1, 2019 to May 14, 2020 using the keywords “novel coronavirus”, “COVID-19” or “SARS-CoV-2”. We included published or in press peer-reviewed cross-sectional, case series, and case reports providing clinical signs, imaging findings, and/or laboratory results of pediatric patients who were positive for COVID-19. Risk of bias was appraised through the quality assessment tool published by the National Institutes of Health. PROSPERO registration # CRD42020182261.

Findings: We identified 131 studies across 26 countries comprising 7780 pediatric patients. Although fever (59.1%) and cough (55.9%) were the most frequent symptoms 19.3% of children were asymptomatic. Patchy lesions (21.0%) and ground-glass opacities (32.9%) depicted lung radiograph and computed tomography findings, respectively. Immunocompromised children or those with respiratory/cardiac disease comprised the largest subset of COVID-19 children with underlying medical conditions (152 of 233 individuals). Coinfections were observed in 5.6% of children and abnormal laboratory markers included serum D-dimer, procalcitonin, creatine kinase, and interleukin-6. Seven deaths were reported (0.09%) and 11 children (0.14%) met inclusion for multisystem inflammatory syndrome in children.

Interpretation: This review provides evidence that children diagnosed with COVID-19 have an overall excellent prognosis. Future longitudinal studies are needed to confirm our findings and better understand which patients are at increased risk for developing severe inflammation and multiorgan failure.

Funding: Parker B. Francis and pilot grant from 2R25-HL126140. Funding agencies had no involvement in the study.

© 2020 The Author(s). Published by Elsevier Ltd. This is an open access article under the CC BY-NC-ND license.

(<http://creativecommons.org/licenses/by-nc-nd/4.0/>)

Introduction

In December 2019, an unprecedented number of pneumonia cases presented in adult individuals from Wuhan, China [1]. Despite rapid action by the Chinese government and health officials, the number of similar presenting cases continued to rise at an alarming rate [2]. By January 2020 an emerging zoonotic agent, known as Severe Acute Respiratory Syndrome Coronavirus 2 (SARS-CoV-2), was identified in respiratory samples in patients diagnosed with pneumonia who subsequently developed respiratory failure [1]. The spread of SARS-CoV-2 from human to human, through respiratory droplets, has now resulted in a worldwide outbreak, now classified as a pandemic by the World Health Organization [3].

As of June 3rd, 2020, there has been more than 6.4 million confirmed cases worldwide and >380,000 fatalities [4]. Most symptomatic cases have occurred in the adult population, characterized by fever, cough, malaise, and frequent hospitalization [1]. Accordingly, most of the published data is derived from adults with coronavirus disease 2019 (COVID-19) who were hospitalized in China [5]. As the pandemic continues, we are now observing numerous reports describing the clinical presentation and hospital course of children with confirmed COVID-19 [5].

What is currently known is that children have milder symptoms and are less likely to be hospitalized when compared to adults [6]. However, on May 14th, 2020 the United States Centers for Disease Control and Prevention (CDC) released a health advisory reporting a multisystem inflammatory syndrome in children (MIS-C) associated with COVID-19 [7]. This statement stemmed from a subset of pediatric patients manifesting with severe inflammation, multi-organ failure, and testing positive for SARS-CoV-2 [8,9].

* Corresponding author.

E-mail address: MoreiraA@uthscsa.edu (A. Moreira).

† Co-1st author.

Our goal was to conduct a systematic review: (i) to understand the clinical picture and presentation of pediatric patients with confirmed COVID-19, and (ii) to provide an initial observation of the signs, symptoms, and laboratory findings of pediatric patients who developed MIS-C.

Methods

2.1 Search strategy and selection criteria

Our methods adhere to the guidelines established by Preferred Reporting Items for Systematic Reviews and Meta-Analyses (PRISMA). Our study protocol was registered with PROSPERO (International Prospective Register of Systematic Reviews) under the following identifier # CRD42020182261.

We conducted a systematic search in the following databases: PubMed, LitCovid, Scopus, and the WHO COVID-19 database. Additionally, we searched for studies that included the following terms: "novel coronavirus, COVID-19, 2019-nCoV, SARS-CoV-2, pediatric, child, and neonate" into the freely accessible research domains of JAMA, Lancet, NEJM, CHEST, and Google Scholar. The last search was performed on May 14th, 2020 and was not limited by language (translation performed with Google Translate).

We included published or in press peer-reviewed articles reporting pediatric cases of confirmed COVID-19. We accepted the following types of studies: cross-sectional, cases series, case-control, case reports, review articles, opinion papers, and letters to journal editors that incorporated clinical, laboratory, imaging, and hospital course of pediatric patients. The pediatric population included neonates, children, and young adults up to 21 years of age. We set the upper limit of age to 21 years as several countries use this number to stratify their pediatric versus adult data. Patients were included if SARS-CoV-2 was detected by real time reverse transcription polymerase chain reaction (RT-PCR) in nasopharyngeal, throat, blood, or stool samples at any point of their clinical evaluation. Suspected cases of COVID-19 without positive RT-PCR were excluded in this study. Furthermore, we also excluded *in vitro* studies or manuscripts focusing on animal experiments.

Screening by title and abstract was conducted independently by at least two investigators (AH, KC, or AxM). A third investigator (AM) was consulted to resolve differences of opinion in either phase. Subsequent full-text review and data extraction was conducted by all investigators using a standardized online form shared among the authors. Data retrieved from each article was cross-checked by at least two independent investigators.

Our outcomes of interest were to describe the clinical signs, imaging findings, and laboratory results characteristic of pediatric patients with confirmed COVID-19. Also, we wanted to provide an initial description of children with confirmed diagnosis of SARS-CoV-2 who develop MIS-C. We used the definition by the CDC to define MIS-C

(e.g., fever, laboratory evidence of inflammation, and evidence of clinically severe illness requiring hospitalization, with multisystem (≥ 2) organ involvement with no alternative diagnosis, and positive for SARS-CoV-2 infection) [7]. Control cases were patients from the same case series who did not meet criteria for MIS-C or studies that presented individual patient data where MIS-C could be definitively ruled out.

2.2 Data collection and risk of bias assessment

Data extraction was performed by all investigators and compared by at least two investigators for consistency. Data collected included the type of article (e.g., case series), country of origin, number of pediatric patients, demographic information, and all clinical symptoms (e.g., fever, cough), laboratory values (e.g., CBC, LFTs, BMP), imaging

studies (e.g., chest x-ray, CT, MRI), clinical outcomes (e.g., ICU admission), and treatments provided (e.g. antivirals).

The risk of bias for observational studies was appraised through the quality assessment tool published by the National Institutes of Health [10]. We opted to use this guide as the development of the assessment tool was conducted rigorously by researchers in the Agency for Healthcare Research and Quality Evidence-Based Practice Centers, the Cochrane Collaboration, the United States Preventive Services Task Force, the Scottish Intercollegiate Guidelines Network, the National Health Service Centre for Reviews and Disseminations, and consulting epidemiologists. Moreover, it was a preferred tool in a systematic review on risk of bias assessments used in PROSPERO-registered protocols [11]. Risk of bias was assessed independently by at least two investigators and disagreements were resolved by a third researcher (AM). Furthermore, the level of evidence was assessed according to Sackett [12].

2.3 Data analysis

All laboratory data were converted to similar units and presented as mean with standard deviation (SD). Laboratory information presented as median (IQR) were converted to mean (SD), and denoted when unable to convert [13]. Publications that provided multiple timepoints (e.g., hospital course of individuals) for laboratory results were gathered and averaged. If the symptom was present anytime during the hospitalization, it was considered positive and characterized as a count with percent. A similar approach was taken for imaging information. Means, standard deviations, and proportion ratios were calculated using Microsoft Excel.

Statistical analyses between COVID-19 pediatric patients with/without MIS-C was conducted on STATA v.13. All statistical tests were two-sided, and significance was defined as a p value < 0.05 . Continuous data was summarized as mean (standard deviation) or median (interquartile range) and assessed by Student's t-test or Wilcoxon rank sum. Categorical data was summarized as counts (percent) and analyzed by Fisher's exact test.

2.4 Role of the funding source

The funder of the study had no role in study design, data collection, data analysis, data interpretation, or writing of the report.

Results

The search yielded 1,142 studies. After removing 237 duplicates, 905 articles were reviewed by abstract and title. After initial screening, only 319 articles met inclusion criteria and underwent full text evaluation. Publications that were retracted, or consisted of editorials, reviews, or commentaries that did not meet our criteria were removed, generating a final list of 131 articles (see Fig. 1).

Studies included in this review were published between January 24th to May 11th, 2020. Eight studies were cross sectional, 75 were case series, and 48 were case reports (refer to Table 1). Twenty-six countries were represented with the largest data derived from 2572 children from the United States. China comprised 64.1% of the studies included in this review. Appendix 1 displays publications by the country of origin.

Twenty of the publications pertained to the neonatal population and the ages extended from an extremely premature neonate at 26 weeks gestation to 20 years of age. The level of evidence for all of the studies was 5 (1 is highest, 5 is lowest) and the risk of bias scores were between 2 to 7 (1 is lowest, 9 is highest, refer to Appendix 2).

A total of 7780 COVID-19 positive children were included. Fifty six percent of the individuals were male (Table 2).

The mean age was 8.9 years (SD 0.5) and 75.6% of patients were exposed to a family member who was diagnosed with COVID-19. The

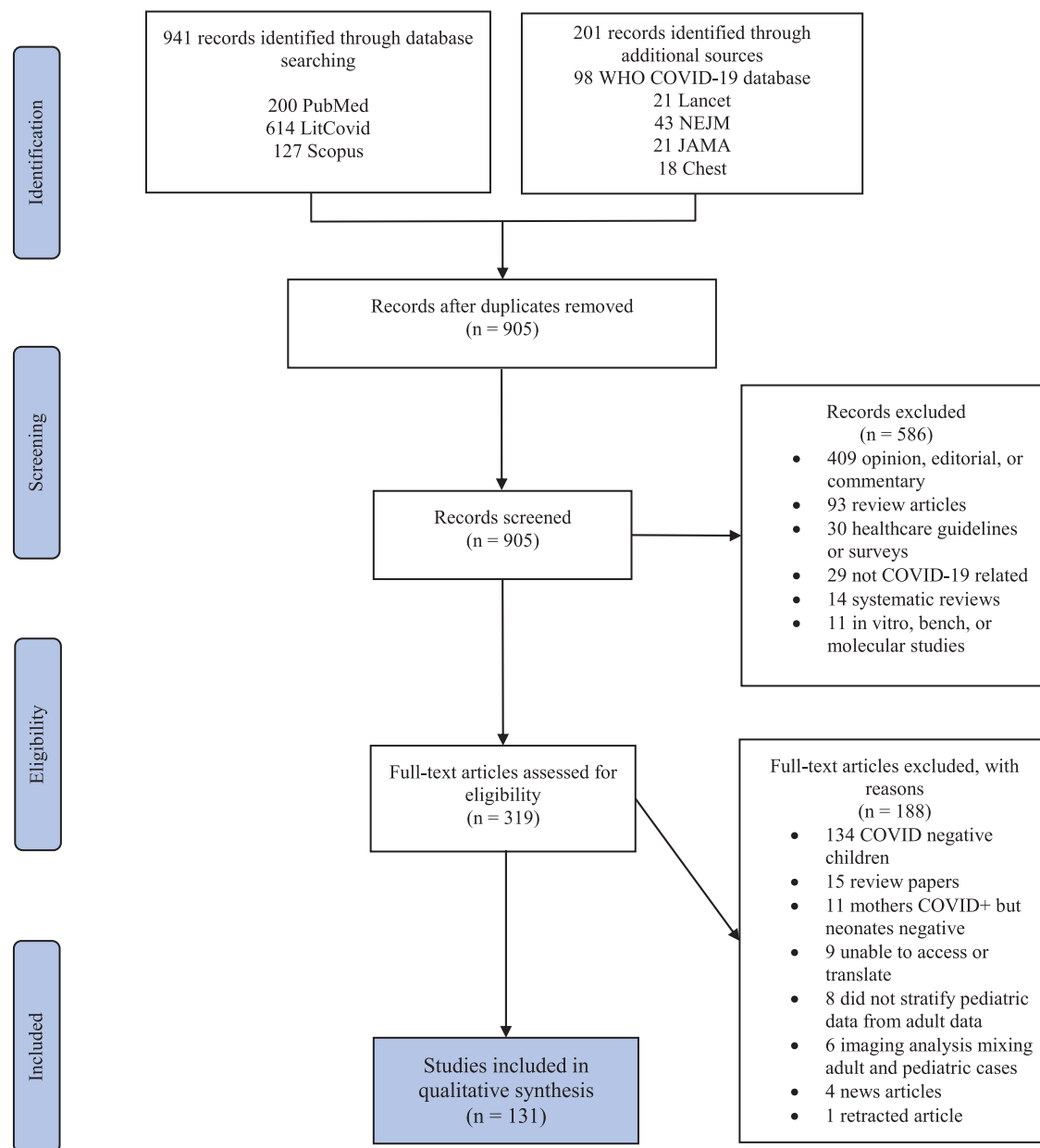


Fig. 1. PRISMA flow diagram.

most common method for detection of the virus was through nasopharyngeal or throat swab (86.5%). Need for intensive care unit observation or treatment was low (3.3%). Twenty studies (n=655 individuals) reported an underlying medical condition; COVID-19 positive children who were immunosuppressed or had a history of a respiratory or cardiac condition comprised the majority (65%). Moreover, influenza and Mycoplasma were the most common co-infections (see Table 3).

Table 4 summarizes clinical symptoms and imaging findings in COVID-19 confirmed pediatric patients. No symptoms were described in 456 of 2367 patients (19.3%), while the two most common symptoms were fever (59.1%), and cough (55.9%). While upper respiratory symptoms were characteristic of COVID-19, some patients presented with mild or often overlooked symptoms such as fatigue, abdominal pain, or decreased appetite [14–16]. Table 4 also summarizes imaging findings. According to chest x-ray and computed tomography (CT), 23.6% and 18.9% had normal results, respectively. Patchy lesions were observed in 105 of 501 patients on chest

radiography and bilateral ground glass opacities were the most frequent CT abnormality.

Complete blood counts were the most common laboratory results described (see Table 5). Overall, leukocytes were within normal values ($7.1 \times 10^3/\mu\text{L}$), whereas neutrophils were mildly decreased (44.4%) while lymphocytes were marginally elevated (39.9%). Markers of liver and renal function were normal. Four serum inflammatory markers were above the mean: D-dimer, procalcitonin, creatine kinase, and interleukin-6.

Sixty-six studies (n=614 individuals) provided information regarding treatments. Interferon was the most commonly administered drug (41.0%), followed by empiric antibiotics (20.2%). Of note, glucocorticoids, and intravenous immunoglobulin was used in 4.1% and 3.1% of patients, respectively. Complications we evaluated were rare and only described in 21 studies. There were 7 cases of kidney failure (0.09%), 19 cases of shock (0.24%), and 42 children were intubated (0.54%). More details on treatments provided and complications can be found in Table 6.

Table 1
Study characteristics.

#	First author	Study type	Country	N	Age (years)	Male N	Clinical symptoms	Laboratory findings	Imaging characteristics	Therapy	ICU (N)
1	Aghdam, M	Case report	Iran	1	0.042	1 (100%)	Fever, lethargy, mottling, respiratory distress	Normal CBC, BUN, Cr, and ABG	Normal CXR, no lung CT	Fluids, oxygen, anti-biotics, oseltamivir	1
2	Almeida, F	Case report	Brazil	1	10	0 (0%)	Fever, cough, sore throat, gross hematuria	Urinalysis showed normal shaped red cells	NR	NR	0
3	Alonso Diaz, C	Case report	Spain	1	0.022	0 (0%)	Tachypnea, retractions, and desaturations 9 days after birth	Normal CRP and capillary gas	CXR: ground glass opacities in the right perihilar region	Observation	1
4	An, P	Case report	China	1	3	0 (0%)	Asymptomatic	NR	CT: bilateral consolidation and ground-glass opacities	Antibiotic	0
5	Andina, D	Case series*	Spain	1	NR	0 (0%)	Mild gastrointestinal symptoms and chilblains on feet	NR	NR	Oral analgesic, anti-histamine, topical corticosteroids for some patients	NR
6	Andre, N	Case series	France	5	9.6	2 (40%)	Respiratory compromise in children with oncologic disease	NR	NR	NR	5
7	Bi, Q	Case series	China	32	NR	NR	Time to recovery better in children <9 years of age (17.5 days) vs. 10-19 years (19.1 days), secondary household attack rate ~7.25%	NR	NR	NR	NR
8	Cai, J	Case series	China	10	6.17	4 (40%)	7 patients with fever, 6 with cough, 4 with sore throat, 0 with diarrhea, all patients were symptomatic treatment + antibiotics (n=5)	↑CRP (n=8), ↑PCT (n=6), ↑LDH (n=3); ↑WBC (n=3), ↑D-dimer (n=2) 0	CXR: unilateral patchy infiltrates (n=4)	Symptomatic treatment (n=5), symptomatic	
9	Cai, JH	Case report	China	1	7	1 (100%)	Fever, cough, rhinorrhea, nausea	↑WBC, CRP, and D-dimer	CXR: Bilateral thickening of lung texture	Observation, Chinese medications	0
10	Calvo, C	Cross sectional	Spain	5	2.5	0 (0%)	NR	NR	NR	NR	NR
11	Canarutto, D	Case report	Italy	1	0.088	1 (100%)	Fever, cough, and rhinorrhea	Mild neutropenia, monocytosis, and reactive lymphocytes on blood smear	CXR:normal	NR	NR
12	Carrabba, G	Case report	Italy	1	0.67	1 (100%)	Mild temperature, dry cough	NR	CXR:no overt interstitial pneumonia but mild veiling opacity of left lung, no lung CT	Neurosurgery for shunt revision x2	0
13	CDC COVID 19 Response team	Case series	USA	2572	9.8	1408 (57%)	Symptom data available for 291 patients: 56% of pediatric patients reported fever, 54% reported cough, and 13% reported shortness of breath, 53 of 78 cases did not report symptoms, 23% (n=80) of 345 patients had at least 1	NR	NR	NR	15

(continued on next page)

Table 1 (Continued)

#	First author	Study type	Country	N	Age (years)	Male N	Clinical symptoms	Laboratory findings	Imaging characteristics	Therapy	ICU (N)
14	Cela, E	Case series	Spain	15	10.1	14 (93%)	underlying medical condition, 3 deaths Fever (n=10), cough (n=6), asymptomatic (n=2), hypoxemia (n=2), all patients with oncologic disease	median WBC 3.2, median lymphocyte 18.2%, median D-dimer normal	CXR: normal (n=6), pneumonia (n=4), peribronchial cuffing (n=4)	Hydroxychloroquine (n=1), tocilizumab & lopinavir/ritonavir (n=1), oxygen (n=2), antibiotic (n=2), remdesivir (n=1), no treatment (n=4)	NR
15	Chacon-Aguilar, R	Case report	Spain	1	0.07	1 (100%)	Paroxysmal episodes with generalized hypertonia, fever, rhinorrhea, vomiting, diarrhea	CBC, liver and kidney studies normal, ↑CK (380 U/L), ↑LDH (390 U/L), normal CRP	NR	Antibiotics	0
16	Chan, JF	Case series*	China	1	10	1 (100%)	Asymptomatic	Normal CBC, fibrinogen, CRP, Cr, LDH, and CK, ↑alkaline phosphatase	CT: bilateral ground-glass opacities	NR	0
17	Chang, D	Case series	China	2	8.5	NR	Fever, cough	NR	NR	NR	0
18	Chen, F	Case report	China	1	1.08	1 (100%)	Fever, shortness of breath, vomiting, diarrhea, myalgia/fatigue, cold limbs with poor perfusion	Normal ABG, coagulation profile; LFTs, ↑BUN, Cr, CK, serum amyloid, IL-6, IL-10	CXR: large blurred image of the upper and lower right lung; CT: enhanced texture of both lungs, large consolidation on the right, ground-glass shadow	Continuous dopamine, IV bolus, ventilator assistance, correction of acidosis, interferon, glucocorticoid, oseltamivir, antibiotics, abdominal decompression	1
19	Chen, H	Case report	China	1	12	1 (100%)	Fever, cough, abdominal pain, sputum production, no vomiting	Normal CBC, ↑CRP	CT: pneumonia in the right upper lung, followed by bilateral ground-glass opacities	Antibiotics, arbidol, and supplemental oxygen	NR
20	Chen, J	Case series	China	12	14.5	6 (50%)	Cough (75%), fever (58.3%), diarrhea (33%), dizziness (16.7%), sore throat (16.7%)	Normal CBC, LFTs, BUN, PT, ↑total B and T cells when compared to adults, but comparable NK cell, IgM, IgG, and C3	Ground-glass opacity was the most common finding on chest CT	All patients received interferon, 8 received lopinavir/ritonavir, and 2 received ribavirin	0
21	Cui, Y	Case report	China	1	0.15	0 (0%)	Pharyngeal hyperemia, rhinorrhea, cough, sputum	Slightly elevated IgM, lymphocyte, and platelet counts; normal Hgb, D-dimer, PTT, PT, CRP, ESR, and renal function	CT: Unilateral ground-glass opacity in the right lung and unilateral consolidation	Interferon, antibiotic, ursodeoxycholic acid, Chinese medicine	1
22	de Rojas, T	Case series	Spain	15	10.1	14 (93%)	10 patients had fever, 6 patients had cough, 1 with hypoxemia, and 2 asymptomatic patients; all patients had an underlying oncologic disease	Median WBC count was 3,195 and median lymphocyte count was 580	CXR: normal (n=6), pneumonia (n=4), peribronchial cuffing (n=4)	11 patients received hydroxychloroquine and 2 received antibiotics, tocilizumab (n=1), lopinavir-ritonavir (n=1), glucocorticoid	0

(continued on next page)

Table 1 (Continued)

#	First author	Study type	Country	N	Age (years)	Male N	Clinical symptoms	Laboratory findings	Imaging characteristics	Therapy	ICU (N)
23	Denina, M	Case series	Italy	8	4.2	5 (63%)	Fever (n=6), dry cough (n=5), dyspnea (n=3), pharyngeal congestion (n=3), vomiting or diarrhea (n=3), hypoxemia (n=2)	NR	CXR: pulmonary consolidation (n=1), ground-glass opacities (n=4); LUS: confluent B-lines (n=5), subpleural consolidations (n=2)	(n=1), and remdesivir (n=1) Oxygen (n=2)	NR
24	Dona, D	Case series	Italy	2	0.29	NR	Fever (n=1) diarrhea (n=1), respiratory symptoms in both	NR	NR	NR	0
25	Dong, L	Case report	China	1	0.003	0 (0%)	Asymptomatic	Nasopharyngeal test was negative, but IgM and IgG were elevated 2 hours after birth, ↑IL-6, IL-10, LDH	CT: normal	NR	1
26	Dong, Y	Case series	China	731	10	420 (58%)	315 mild illness, 300 moderate illness, 18 severe and 3 critically ill, 94 asymptomatic children	NR	NR	NR	NR
27	Du, W	Case series	China	14	7.1	6 (43%)	Fever (n=5) and cough (n=3) were commonly reported; Eight (57.1%) were asymptomatic	↑LDH (n=7), ↑PCT (n=5), ↑D-dimer (n=5), ↑CK (n=4), leukopenia (n=4), ↑IL-6 (n=1)	CT: bilateral lung injury (n=6) and unilateral (n=5)	NR	0
28	Fan, Q	Case report	China	1	0.25	0 (0%)	Fever and diarrhea	Neutrophilia (86.2%), lymphopenia (7.1%)	CT: normal	Supportive care	0
29	Feng, K	Case series	China	15	7	4 (33%)	Asymptomatic (n=8), fever (n=5), cough or nasal congestion (n=1)	↓WBC (n=8), normal WBC (n=7)	CT: ground glass lesions (n=7), no lesions (n=6), patchy shadow (n=2)	NR	NR
30	Ferrazzi, E	Case series	Italy	3	0.003	NR	1 neonate with gastrointestinal and respiratory symptoms 3 days after birth	NR	NR	NR	1
31	Genovese, G	Case report	Italy	1	8	0 (0%)	Fever, cough, papulovesicular rash to trunk	Normal complete blood count, CRP, liver and kidney function, mild thrombocytopenia (105k)	NR	NR	NR
32	Guan, W	Case series	China	9	NR	NR	NR	NR	NR	NR	NR
33	Gubjartsson, D	Cross sectional	Iceland	1321	NR	NR	NR	NR	NR	NR	NR
34	Han, M	Case report	Korea	1	0.07	0 (0%)	Fever, cough, and vomiting; viral shedding in urine and stool for 10 and 18 days, respectively	First CBC with mild neutropenia (817 per mm3)	CXR: normal	No antibiotics or antivirals	0
35	Han, Y	Case series	China	7	4	4 (57%)	Fever (n=5), cough (n=5), shortness of breath (n=3), vomiting (n=4), diarrhea (n=4), sore throat (n=1), myalgia (n=1)	↑BNP (n=5), ↑CK (n=4), ↑PCT (n=3), ↑AST (n=3), ↑LDH (n=2), ↑CRP (n=2)	Pneumonia on CT and CXR (n=5)	Oxygen therapy (n=2) glucocorticoids (n=1)	0
36	Hrusak, O	Cross sectional	Czech Republic, USA, Italy, Spain, Switzerland, Denmark, Austria, Sweden, Belgium, Netherlands	9	NR	NR	Fever (n=7) and diarrhea (n=1) were the most common symptoms in this cohort of children with oncologic disease	Lymphopenia (n = 1), neutropenia (n=5)	Normal CXR in 1 patient, all others NR	Antibiotics (n=2) lopinavir/ritonavir (n=1) hydroxychloroquine (n=2)	0

(continued on next page)

Table 1 (Continued)

#	First author	Study type	Country	N	Age (years)	Male N	Clinical symptoms	Laboratory findings	Imaging characteristics	Therapy	ICU (N)
37	Hu, X	Case series*	China	1	0.004	1 (100%)	Asymptomatic	WBC, Hgb, Plts, CRP, Cr, ALT normal, ↑PCT (n=6)	Normal CXR=1; no CT data	NR	0
38	Ibrahim, L	Case series	Australia	4	13.1	1 (25%)	Sore throat (n=4), headache/dizziness (n=3), cough (n=2), fever (n=1)	NR	NR	None	0
39	Ji, L	Case series	China	2	12	2 (100%)	Fever and diarrhea (n=1)	↑WBC (n=1), ↑CRP (n=1)	CT: normal (n=2)	Symptomatic treatment, oral probiotic	0
40	Ji, T	Case series	China	19	NR	NR	Asymptomatic (n=9)	NR	NR	NR	NR
41	Jiang, S	Case series	China	2	5.08	0 (0%)	Fever, cough, and vomiting in both patients	↑WBC, neutrophil count, CRP, PCT, serum amyloid A (n=1)	CT: normal (n=1), bilateral ground-glass opacities with patchy shadows (n=1)	Antibiotics (n=2), oseltamivir (n=1), glucocorticoids (n=1), IVIG (n=1)	1
42	Jones, V	Case report	USA	1	0.5	0 (0%)	Fussy, conjunctivitis, dry cracked lips, prominent tongue papilla, polymorphous maculopapular rash, swelling of hands and feet, fever, anorexia	WBC with bandemia, ↑CRP, normal ESR, BMP, and LFTs	CXR: faint opacity in left midlung	IVIG and acetylsalicylic acid	NR
43	Kam, K	Case report	Singapore	1	0.5	1 (100%)	Asymptomatic initially, followed by fever	Viremia, normal CBC, LFTs	NR	NR	NR
44	Kan, M	Case report	USA	1	0.02	0 (0%)	Fever, tachycardia, cough; underlying condition of hydronephrosis and duplicating renal system	Leukopenia, lymphopenia, neutropenia, normocytic anemia, normal platelets, normal CRP	NR	Bolus, antibiotic, antipyretics	0
45	Korean Society of Infectious Diseases	Cross sectional	Korea	201	NR	NR	NR	NR	NR	NR	NR
46	Lai, W	Case series	China	2	14	2 (100%)	2 with dry cough, 2 with fever, and 1 with malaise	NR	CT: unilateral patchy ground-glass opacities (n=2)	Antivirals, supportive	0
47	Le, H	Case report	Vietnam	1	0.25	0 (0%)	Rhinorrhea and nasal congestion, fussy	Normal CBC, CK, LDH, CRP, and PCT	CXR: normal	Antibiotic	NR
48	Leva, E	Case series	Italy	16	NR	NR	All patients with fever and cough	NR	NR	NR	4
49	Li, H	Case series	China	40	5.1	23 (58%)	Cough (n=27), fever (n=21), myalgia (n=4), diarrhea (n=4), rhinorrhea (n=2), sore throat (n=2)	Normal CBC, CRP, PCT, ↑CD3 ⁺ , CD8 ⁺ lymphocyte (n=40), ↑% of CD3 ⁺ (n=40), and ↓percentage of CD19 ⁺ lymphocyte (n=40)	CT: unilateral (n=13), bilateral (n=26) ground-glass opacities, normal (n=1)	Interferon (n=40), oseltamivir (n=20), IVIG (n=4), steroids (n=3), azithromycin (n=13), mechanical ventilation (n=1)	1
50	Li, J	Case report	China	1	0.67	0 (0%)	Cough	WBC and differential, PT, D-dimer, LFTs and renal function normal, ↑CRP	Normal CT	Interferon	0
51	Li, M	Case report	China	1	0.006	1 (100%)	Patient had no fever or cough	NR	NR	NR	0
52	Li, W	Case series	China	4	7.2	4 (100%)	Cough	NR	NR	NR	NR

(continued on next page)

Table 1 (Continued)

#	First author	Study type	Country	N	Age (years)	Male N	Clinical symptoms	Laboratory findings	Imaging characteristics	Therapy	ICU (N)
53	Li, Wei	Case series	China	5	3.4	4 (80%)	Asymptomatic (n=4), 1 patient with rhinorrhea, cough, sore throat, and fever	↑WBC (n=2), ↑CRP (n=1)	CT: patchy ground-glass opacities (n=3), normal (n=2)	IVIg (n=5), antivirals (n=2), montelukast (n=3), interferon (n=2)	NR
54	Li, Y	Case series	China	2	4	1 (50%)	Cough and rhinorrhea (n=1)	↓neutrophils (n=1), ↑CRP (n=1), normal coagulation profile, LFTs and renal function in both patients	CT: bilateral spots upper lobes (n=1), increased bronchovascular bundles bilaterally (n=1)	Oxygen (n=1)	0
55	Lin, J	Case report	China	1	7	0 (0%)	Nasal congestion and dry cough; no fever, dyspnea, or diarrhea	NR	CT showed no signs of pneumonia	Supportive treatment, oseltamivir, and interferon	NR
56	Liu, M	Case series	China	5	6.4	4 (80%)	3 were asymptomatic, 2 patients with fever and dry cough	Normal WBC, mild neutropenia (n=3)	CT: unilateral (n=3) and bilateral (n=1) ground-glass opacities	Interferon (n=4), ribavirin (n=3)	NR
57	Liu, W	Case series	China	6	3.5	2 (33%)	High fever and cough in all patients; vomiting (n=4)	White cells (n=4), lymphocytes (n=6), and neutrophils (n=3) were decreased	CT: patchy shadows bilaterally (n=3), patchy ground-glass opacities in both lungs (n=1), normal (n=1)	Oseltamivir (n=6), glucocorticoid (n=4), ribavirin (n=2), IVIG (n=1)	1
58	Liu, Y	Case report	China	1	10	1 (100%)	Asymptomatic	Normal CBC, LFTs, ↑LDH, borderline ↑CRP	CT: ground-glass opacity and pleural effusion	Ribavirin, interferon	0
59	Locatelli, A	Case report	Italy	1	16	1 (100%)	Mild diarrhea and chilblain-like lesions to fingers and a toe	Coagulation, autoimmunity, cryoglobulins normal	NR	NR	NR
60	Lou, X	Case series	China	3	4.8	1 (33%)	All patients had fever; 2 with fatigue, nasal congestion, diarrhea, and headache	NR	NR	Interferon (n=2)	0
61	Lu, X	Case series	China	171	6.4	104 (61%)	Fever (41.5%), pharyngeal erythema (46.2%), diarrhea (8.8%), asymptomatic (15.8%), 1 death	↓WBC (26.3%), lymphopenia (3.5%), ↑PCT (64%), ↑CRP (19.7%), ↑D-dimer (14.1%), ↑AST (14.6%)	CT: ground glass opacity (32.7%), unilateral or bilateral patchy shadowing (31%), interstitial abnormalities (1.2%)	NR	3
62	Lu, Y	Case series	China	9	7.8	5 (56%)	Fever (n=6), cough (n=3), asymptomatic (n=1)	All WBC counts were normal	CXR: no overt abnormality (n=5); CT: no overt abnormality (n=4), patch ground-glass opacities (n=4)	NR	0
63	Lu, Yingying	Case series	China	110	5.8	59 (53%)	Cough and dyspnea (51.8%), followed by fever (50.9%) were the most common symptoms, 26 (23.6%) patients had gastrointestinal symptoms, 29 (26.4%) were asymptomatic	Symptomatic patients were more likely to have a ↓Hgb (16.4% vs. 0%), ↑AST (23.5% vs. 0%), and trended towards an ↑IL-6 (12% vs. 0%)	64 patients had a chest x-ray demonstrating pneumonia	All received antivirals, interferon was the most frequently used, Chinese medication (n=22)	0
64	Ma, H	Case series	China	50	3.3	28 (56%)	32 with fever, 22 with cough, 8 with rhinorrhea, 1 with sore throat, 2 with myalgia, 3 with diarrhea, 6 with no symptoms	Leukocytosis (n=2), leukopenia (n=19), polycythemia (n=2), thrombocytopenia (n=7), ↑CRP (n=10)	CT: ground-glass opacities (n=29), local patchy shadowing (n=9), normal (n=7)	NR	NR

(continued on next page)

Table 1 (Continued)

#	First author	Study type	Country	N	Age (years)	Male N	Clinical symptoms	Laboratory findings	Imaging characteristics	Therapy	ICU (N)
65	Ma, H ₂	Case series	China	22	5.5	12 (55%)	Fever (n=13), dry cough (n=5), shortness of breath (n=1), asymptomatic (n=2)	NR	CT: ground-glass shadows (n=6), consolidation (n=4), consolidation and ground-glass shadows (n=6), bronchial pneumonia-like changes (n=3), normal (n=3)	NR	NR
66	Ma, Y	Case series	China	115	NR	73 (64%)	Asymptomatic (n=61), fever (n=29), cough (n=47), rhinorrhea (n=47), gastrointestinal symptoms (n=3)	Normal WBC (n=88), ↓WBC (n=23); lymphocytes normal (n=60), ↑lymphocytes (n=40); normal neutrophils (n=77), ↑neutrophils (n=32), ↑ALT (n=11), ↑CK-MB (n=34), ↑BUN/Cr (n=2)	CT: ground-glass opacities (n=49), normal (n=27)	NR	NR
67	Mansour, A	Case report	Lebanon	1	1.33	0 (0%)	Patient presented with fever, diarrhea, and decreased activity	Leukocytosis, elevated platelets, elevated CRP, decreased hemoglobin/hematocrit	CXR: unilateral, large consolidation with bronchial infiltrate	Hydration and antibiotics	0
68	Mao, L	Case report	China	1	1.16	1 (100%)	Patient presented with fever, cough, congestion, rhinorrhea, decreased appetite	Normal CBC, PCT, LFTs, renal function, D-dimer; normal T cell, B cell, and NK cell, ↑CRP	CT: unilateral ground-glass opacities in right lower lung	Interferon and supportive	0
69	Mizumoto, K	Case series	Japan	3	NR	NR	Asymptomatic (n=2)	NR	NR	NR	NR
70	Morey-Olive, M	Case series	Spain	2	3	1 (50%)	Low grade fever (n=2)	Abnormal liver enzymes and coagulation parameters in 1 patient	NR	NR	0
71	Munoz, A	Case report	USA	1	0.06	1 (100%)	Nasal congestion, tachypnea, reduced feeding, subsequent pneumothorax	↑PCT (6.53 ng/mL) and ↑CRP (172 mg/L)	CXR: bilateral linear opacities and consolidation of right upper lobe	Mechanical ventilation, antibiotics, hydroxychloroquine, vasopressors	1
72	Nathan, N	Case series	France	5	0.18	5 (100%)	All had fever, 4 patients with hypotonia or drowsiness and moaning, 4 with cough and rhinorrhea	CBC normal, ↑CRP (n=3), ↑PCT (n=1)	Normal CXR in 4 patients, 1 patient with hyperinflation	Antipyretics	0
73	Ng, K	Case series	UK	8	0.39	2 (25%)	Fever (n=5), anorexia (n=4), tachypnea (n=2), skin mottling (n=1)	2 patients had neutropenia and thrombocytosis	2 patients had some opacities on CXR	4 patients treated with broad-spectrum antibiotics	2
74	Odievre, M	Case report	France	1	16	0 (0%)	Fever, followed by acute chest syndrome in a patient with sickle cell disease	↑CRP, ↑D-dimer, ↑IL-6, ↑LDH, ↑TNF-α	CT: bilateral pulmonary embolisms and bilateral consolidation with halo sign on right	Acetaminophen, non-invasive ventilation, blood transfusion, anticoagulation, tocilizumab	1
75	Pan, A	Case series	China	536	NR	NR	NR	NR	NR	NR	NR
76	Park, J	Case report	Korea	1	10	0 (0%)	Low-grade fever and sputum production	CBC, CRP normal, stool sample remained positive for 17 days after symptom onset	CT: unilateral patchy or nodular consolidations with peripheral ground-glass opacities	None	0

(continued on next page)

Table 1 (Continued)

#	First author	Study type	Country	N	Age (years)	Male N	Clinical symptoms	Laboratory findings	Imaging characteristics	Therapy	ICU (N)
77	Parri, N	Case series	Italy	100	6	57 (57%)	Fever (n=54), cough (n=44), rhinorrhea (n=22), asymptomatic (n=21), shortness of breath (n=11), nausea (n=10), vomiting (n=10), diarrhea (n=9), myalgia (n=9), sore throat (n=4), headache (n=4); 27 patients with underlying medical conditions	WBC normal (n=40), ↓WBC (n=11), lymphocytopenia (n=14), ↑PCT (n=4), ↑LDH (n=22), ↑ALT (n=8), ↑AST (n=10)	CXR: interstitial abnormality (n=14), normal (n=15), consolidation (n=6), pleural effusion (n=1); LUS: interstitial syndrome (n=9), small sub-pleural consolidations (n=4)	Non-invasive ventilation; mechanical ventilation (n=1)	9
78	Patek, P	Case report	USA	1	0.04	1 (100%)	Fever, hypoxemia	Normal CBC, mild elevation to AST and ALT, CSF unremarkable	CXR: bilateral perihilar streaking without focal consolidation	Oxygen, empiric antibiotics, acyclovir	1
79	Patel, P	Case report	USA	1	12	0 (0%)	Fever, cough, vomiting, hematuria, and respiratory failure	Severe thrombocytopenia (<10k per μ L), elevated inflammatory markers (CRP, PCT, ferritin)	CXR: bilateral diffuse airspace opacities and small pleural effusion	IVIg, corticosteroids, mechanical ventilation, nitric oxide, azithromycin, hydroxychloroquine, tocilizumab	1
80	Piersigilli, F	Case report	Belgium	1	0.002	0 (0%)	No COVID-related symptoms; child is an extremely premature neonate	↓WBC and lymphopenia	Normal radiographic findings	Continuous positive airway pressure	1
81	Qian, G	Case series*	China	1	1.08	0 (0%)	Asymptomatic	NR	CT: normal	NR	0
82	Qiu, H	Case series	China	36	8.3	23 (64%)	Fever (n=13), cough (n=7), headache (n=3), vomiting/diarrhea (n=2)	Leukopenia (n=7), ↓lymphocytes (n=11), ↑PCT (n=6), ↑CK-MB (n=11)	CXR: ground-glass opacities (n=19)	Interferon (n=36), lopinavir/ritonavir (n=14), oxygen (n=6)	NR
83	Qiu, L	Case report	China	1	0.66	1 (100%)	Fever, cough, wheezing, apnea, mottled skin, petechiae, cold fingers; patient with cardiac history	Initial labs demonstrated lymphopenia, ↓CD3+, ↓CD4+, ↓CD8+, ↓fibrinogen, ↑LDH, normal PCT and renal function	CXR: increased density, profusion, thickened lung texture; CT: multiple ground-glass opacities and patchy, high density shadows	IVIg, lopinavir/ritonavir, methylprednisolone, fluids, electrolytes, pressors	1
84	Robbins, E	Case report	USA	1	0.16	1 (100%)	Fever	CBC within normal limits, CMP normal except for a mildly elevated alkaline phosphatase and calcium	CXR: normal	Antibiotics, supportive	NR
85	Schwierzeck, V	Case series	Germany	3	10	NR	Asymptomatic (n=2), fever (n=1), cough (n=1), nasal congestion (n=1) in patients with renal disease	NR	NR	NR	NR
86	See, K	Case series	Malaysia	4	6.4	3 (75%)	Mild fever and diarrhea (n=1); rhinorrhea (n=1), cough and fever (n=1 mild), asymptomatic (n=1)	NR	CXR: perihilar opacities (n=2)	Antipyretics (n=2), antibiotic (n=1), rehydration (n=1), salbutamol (n=1)	0

(continued on next page)

Table 1 (Continued)

#	First author	Study type	Country	N	Age (years)	Male N	Clinical symptoms	Laboratory findings	Imaging characteristics	Therapy	ICU (N)
87	Shekerdeman, L	Cross sectional	USA, Canada	48	11.3	25 (52%)	11 patients (23%) with multi-organ failure, 73% (n=35) with pulmonary symptoms, 40% (n=19) of children were medically complex	NR	NR	No medications (n=20), hydroxychloroquine (n=21), 17% underwent antiviral therapy, tocilizumab (n=5), mechanical ventilation (n=18), azithromycin (n=8)	
88	Shen, Q	Case series	China	9	7.5	3 (33%)	2 asymptomatic, 3 with fever, 1 with diarrhea, sore throat, or cough, and 1 with fever and diarrhea	↑WBC (n=1), ↑lymphocyte count (n=1), ↑CRP (n=1), ↑ESR (n=4), ↑LDH (n=4)	Normal chest x-ray and lung CT in 7 patients, 2 (22.2%) with small ground-glass opacities	All received oxygen and lopinavir/ritonavir, antibiotic treatment for 5 children, glucocorticoids and IVIG for 1 patient	0
89	Shi, B	Case report	China	1	0.23	1 (100%)	Cough, wheeze, dyspnea	WBC normal, ↑lymphocyte and platelet count; IgG, IgM, IgA, T, B, and NK cells normal, LFTs normal, RSV+	CT: left lower lobe consolidation	Antibiotics, CPAP, IVIG, corticosteroids, interferon, Chinese medication	1
90	Shi, Y	Cross sectional	China	10	6	5 (50%)	NR	NR	NR	NR	0
91	Sieni, E	Case report	Italy	1	1.08	0 (0%)	Fever, vomiting, and diarrhea; patient with underlying oncologic disease	Leukopenia, anemia, thrombocytopenia	CXR: bilateral reticular findings	Antifungal, antibiotics, hydroxychloroquine, lopinavir/ritonavir	0
92	Sinelli, MT	Case report	Italy	1	0.006	1 (100%)	Hypoxemia, perioral cyanosis, poor sucking	Normal complete blood count and C-reactive protein	CT: mild bilateral ground-glass opacities	Oxygen support	1
93	Song, R	Case series	China	7	3.5	1 (14%)	Most asymptomatic, only 2 had fever	Normal WBC, ↓neutrophils, ↑LDH, normal fibrinogen	NR	All patients received supportive care, interferon, lopinavir/ritonavir	NR
94	Song, W	Case series	China	16	7.9	10 (63%)	Asymptomatic (n=8), cough (n=6), fever (n=5)	Leukocytes normal (n=14), CRP normal (n=15), liver, renal, coagulation, electrolytes, and myocardial labs were normal, ↑LDH (n=3)	CT: normal (n=5), bilateral ground-glass opacities (n=8), bilateral consolidation (n=1), patchy/nodular shadow (n=3)	Oseltamivir (n=11), antibiotics (n=9), lopinavir/ritonavir (n=4), Chinese medicine (n=13), arbidol (n=6)	0
95	Su, L	Case series	China	9	3.5	3 (33%)	Asymptomatic (n=6), fever or cough (n=3)	↑CK-MB (n=6), ↓WBC (n=2), LFTs normal, inflammatory markers (CRP, PCT, ESR, IL-6) were normal in all patients, stools positive in 5 children warranting readmission	CT/x-ray: normal (n=5), bronchitis (n=2), pulmonary consolidation and ground-glass opacities (n=1), bronchopneumonia (n=1)	Interferon given to all patients; ribavirin (n=1)	0

(continued on next page)

Table 1 (Continued)

#	First author	Study type	Country	N	Age (years)	Male N	Clinical symptoms	Laboratory findings	Imaging characteristics	Therapy	ICU (N)
96	Sun, D	Case series	China	8	6.6	6 (75%)	Tachypnea (n=8), fever or cough (n=6 each), sputum production (n=4), nausea/vomiting (n=4), diarrhea (n=3), fatigue or headache (n=1 each)	Normal/↑ WBC (n=7), ↑CRP, ↑PCT, ↑LDH (n=6), abnormal LFTs (n=4)	CT/x-ray: multiple patch-like shadows (n=6), ground-glass opacities (n=6), unilateral pneumonia (n=2), bilateral pneumonia (n=6)	Oxygen (n=6), mechanical ventilation (n=2), all patients received antivirals (viral-azole, oseltamivir, interferon), antibiotics (n=5), glucocorticoids (n=5), IVIG (n=4), Chinese medications (n=4)	3
97	Sun, K	Case series	China	13	NR	NR	NR	NR	NR	NR	NR
98	Sun, M	Case series*	China	1	0.02	1 (100%)	NR	NR	NR	NR	0
99	Tagarro, A	Cross sectional	Spain	41	3.3	18 (44%)	Upper respiratory symptoms in 14 (34%), fever (n=11), gastroenteritis or vomiting (n=2)	NR	NR	25 (60%) required hospitalization, 2 received noninvasive ventilation and 1 was intubated	4
100	Tan, X	Case series	China	13	7.9	4 (31%)	Respiratory symptoms (n=7), cough (n=6), low fever (n=6), sore throat (n=2), asymptomatic (n=2)	LFTs, myocardial enzymes, PCT, coagulation, ferritin were normal, ↑ESR (n=3), CRP level increased (13.2 mg/L)	CT: normal (n=7); abnormal: cord-like shadows (n=2), showed ground glass shadows (n=2), had patchy high-density shadow (n=2)	Lopinavir/ritonavir (n=12), interferon (n=10), arbidol (n=6)	0
101	Tan, Y	Case series	China	10	7	3 (30%)	4 patients with fever, 3 with respiratory symptoms, and 1 with vomiting	Normal CBC (n=9), ↑WBC and lymphocytes (n=1), ↑AST (n=2), CRP, LDH, and ferritin normal in all patients, mycoplasma + (n=3)	CT: ground-glass opacities (n=5)	All patients treated with symptomatic support	0
102	Tang, A	Case report	China	1	10	1 (100%)	Asymptomatic	CBC:normal	CT: normal	Arbidol, interferon, Chinese medication	0
103	Tong, Z	Case series*	China	1	12	1 (100%)	NR	NR	NR	NR	NR
104	Turner, D	Case series	Israel, China, Spain, Italy, Korea, USA, UK, Portugal, France	8	16	5 (63%)	Fever (n=3), cough (n=3), myalgia/fatigue (n=4) in children with inflammatory bowel disease	NR	NR	SASA (n=4), infliximab (n=2), thiopurines (n=4), glucocorticoids (n=1)	0
105	Wang, D	Case series	China	31	7.1	15 (48%)	Asymptomatic (n=4), fever (n=20), cough (n=14), fatigue and diarrhea (n=3 each), sore throat (n=2), headache/dizziness (n=3), rhinorrhea (n=2), vomiting (n=2)	↓Leukocytes and lymphocytes (n=2), ↑CRP (10%), ↑PCT (4%), ↑ESR (19%), ↑transaminases (22%), renal function normal	CT lung changes in 14 children, 9 of which showed patchy ground-glass opacities	Interferon (n=10), Antibiotics (n=6), oseltamivir (n=1), 18 were a combination of interferon, oseltamivir, ribavirin, arbidol, and/or lopinavir/ritonavir	0

(continued on next page)

Table 1 (Continued)

#	First author	Study type	Country	N	Age (years)	Male N	Clinical symptoms	Laboratory findings	Imaging characteristics	Therapy	ICU (N)
106	Wang, H	Case report	China	1	8	1 (100%)	Fever	NR	CT: left lower lobe ground-glass opacity	Antiviral and symptomatic treatment	NR
107	Wang, J	Case report	China	1	0.05	1 (100%)	Fever, cough, vomiting, diarrhea	On admission: ↓WBC, ↑monocytes, ↓Plts	CT: bilateral pneumonia and bilateral ground-glass opacities	Interferon	NR
108	Wang, S	Case report	China	1	0.003	1 (100%)	Asymptomatic	Lymphopenia, ↑AST, ↑CK, ↑direct and total bilirubin	CT: unilateral ground-glass opacities	Antibiotic, vitamin K, bolus	1
109	Wang, Y	Case series	China	43	6.92	21 (49%)	The most common symptoms were dyspnea (87.5%), fever (62.5%), and cough (62.5%)	IL-6, IL-10, D-dimer, total bilirubin, and uric acid were elevated in severe cases	All severe cases had lesions on chest CT; ground-glass opacities (n=24), patchy consolidation (n=9)	All severe cases received supplemental oxygen; 5 placed on non-invasive respiratory mode and 3 were intubated	NR
110	Wei, M	Case series	China	9	1.1	2 (22%)	Asymptomatic (n=6), fever (n=4), cough (n=2), rhinorrhea (n=1), sputum production (n=1)	NR	NR	NR	0
111	Wu, P	Case report	China	1	2.83	1 (100%)	Conjunctivitis and eyelid dermatitis	Normal CBC, CRP, CK, liver measurements, ↑CK-MB, ↑LDH, ↓creatinine	Normal lung CT and x-ray	NR	NR
112	Wu, Q	Case series	China	74	6.8	44 (60%)	Asymptomatic (40.5%), cough (32.4%) and fever (27.0%)	Leukopenia (n=4), lymphopenia (n=4), ↑CRP (n=13), ↑PCT (n=2), ↑ESR (n=5); co-infection (n=26)	CT: ground glass opacities (n=9), atypical changes of bronchopneumonia and common viral pneumonia (n=28); normal (n=37)	All patients received interferon, Chinese medications, and antivirals; 27 patients received antibiotics	1
113	Wu, Z	Cross sectional	China	965	NR	NR	NR	NR	NR	NR	NR
114	Xia, W	Case series	China	20	NR	13 (63%)	Cough (n=13), fever (n=12), diarrhea (n=3), dyspnea (n=2), sore throat (n=1), fatigue (n=1)	13 patients with elevated lymphocytes; 2 patients with elevated WBC	CT: consolidation (n=10), ground-glass opacities (n=12), shadow (n=4), nodules (n=3)	NR	NR
115	Xing, Y	Case series	China	3	NR	NR	Fever in all patients, gastrointestinal symptoms (n=1)	SARS-CoV-2 detectable in stool for 1-3 weeks after negative conversion in throat swabs	NR	NR	0
116	Xing, YH	Case series	China	3	4.2	2 (67%)	Fever (n=3), 1 patient had cough and diarrhea	Viral RNA remained detectable in stool for longer than 4 weeks, leukocytosis (n=3), ↑Plts (n=2), ↑PCT (n=1), ↑CRP (n=1), ↑LDH (n=1), ↑D-dimer (n=1)	CT: unilateral ground glass opacities (n=1), unilateral consolidation (n=1), normal (n=1); CXR: patchy shadows (n=1)	Interferon, ribavirin, and Chinese medications were given to all patients	0

(continued on next page)

Table 1 (Continued)

#	First author	Study type	Country	N	Age (years)	Male N	Clinical symptoms	Laboratory findings	Imaging characteristics	Therapy	ICU (N)
117	Xu, Y	Case series	China	10	7.54	6 (60%)	Fever (n=7), cough (n=5), sore throat (n=4), diarrhea (n=3), rhinorrhea (n=2), asymptomatic (n=1)	WBC counts normal, neutropenia (n=4), lymphocytopenia (n=3), lymphocytosis (n=1), ↑PCT (n=5), ↑ESR (n=3), ↑CRP (n=3), ↑LDH (n=2), ↑D-dimer (n=1), ↑ferritin (n=1), normal CK	NR	Interferon (n=10), antibiotics (n=1), IVIG (n=1)	NR
118	Yin, X	Case report	China	1	9	1 (100%)	Fever; no cough, sore throat, or nausea	Lymphopenia, ↑α hydroxybutyrate dehydrogenase, ↑CRP, ↑amyloid, normal PCT and CK	CXR: normal	Antipyretic	NR
119	Yu, N	Case report	China	1	0.004	NR	Dyspnea; no fever, cough, or diarrhea	NR	CXR: mild pneumonia	Observation	1
120	Zeng, L	Case report	China	1	0.05	1 (100%)	Sneezing, vomiting, lethargy, poor feeding	↑lymphocytes, ↓neutrophils and procalcitonin	CT: bilateral enhanced texture and blurred shadows	NR	1
121	Zeng, Lingkong	Case series	China	3	0.003	3 (100%)	Fever (n=2), lethargy (n=2), shortness of breath and cyanosis (n=1), vomiting (n=1)	Leukocytosis (n=2), ↑PCT (n=1), ↑CK-MB (n=1), thrombocytopenia (n=1)	CT: pneumonia (n=3)	Mechanical ventilation (n=1), antibiotics (n=1)	3
122	Zhang, B	Case series	China	46	8.75	29 (63%)	Asymptomatic (n=22), cough (n=15), fever (n=10), rhinorrhea/nasal congestion (n=6), sore throat (n=4), myalgia/fatigue (n=3)	No leukopenia or lymphopenia	CXR: ground glass opacity (n=13), mixed ground glass opacity and consolidation (n=4), local patchy shadowing (n=1), consolidation (n=1)	Most treated with 1-3 antiviral drugs	0
123	Zhang, B ₂	Case series	China	3	9.3	2 (67%)	Asymptomatic (n=2), crying (n=1), fever, cough, and malaise (n=1)	PCT normal (n=3), lymphocytosis (n=1), ↑CRP (n=2), ↑CK (n=1), ↑LDH (n=1)	CT: normal (n=2); CXR: bilateral pneumonia (n=1)	Two hospitalizations for all patients due to persistent SARS-CoV-2 positivity; oseltamivir (n=2), arbidol and lopinavir/ritonavir (n=2), oxygen (n=2), all received Chinese medication	0
124	Zhang, M	Case series*	China	1	15	1 (100%)	Low-grade fever and myalgia	NR	NR	NR	NR
125	Zhang, T	Case series	China	3	7.7	3 (100%)	Fever (n=2), rhinorrhea (n=2), cough (n=1)	Normal electrolytes, liver, and kidney function, normal PCT, LDH, and IL-6; 1 patient with elevated CRP (64.7 mg/L); immunologic profile normal, stool nucleic acid was still positive 10 days after clinical recovery	CT: ground glass opacities (n=2)	Interferon, Chinese medications, and vitamin C for all patients, 1 patient received antibiotics	0

(continued on next page)

Table 1 (Continued)

#	First author	Study type	Country	N	Age (years)	Male N	Clinical symptoms	Laboratory findings	Imaging characteristics	Therapy	ICU (N)
126	Zhang, Y	Case report	China	1	0.25	0 (0%)	Fever and sputum production	Decreased neutrophil count; elevated CRP and platelet count, normal PCT	NR	Ambroxol and aerosolization	0
127	Zhang, Z	Case series	China	4	0.02	3 (75%)	Fever (n=2), shortness of breath (n=1), cough (n=1), vomiting (n=1), and 1 asymptomatic	NR	CT: increased lung markings (n=3)	Supportive	0
128	Zhao, W	Case series	China	2	6.5	NR	NR	NR	NR	NR	NR
129	Zheng, F	Case series	China	25	5.1	14 (56%)	Fever (n=13), cough (n=11), diarrhea (n=3), dyspnea (n=2), vomiting (n=2), abdominal pain (n=2), nasal congestion (n=2)	Median WBC, lymphocytes, CRP, CK within normal limits; lymphopenia (n=10), normal renal and coagulation profile (n=23)	CT: bilateral patchy shadows/consolidations (n=11), unilateral patchy shadows/consolidations (n=5), normal (n=8)	Antiviral therapy (n=12, included interferon, arbidol, oseltamivir, and/or lopinavir/ritonavir), 13 received antibiotics; 2 patients were intubated, and given corticosteroids and IVIG	2
130	Zhou, Y	Case series	China	9	1.58	4 (44%)	Asymptomatic (n=5), fever (n=4), cough (n=2), rhinorrhea (n=1)	normal WBC (n=7), lymphocytosis (n=6), ↑LDH (n=2 of 4 samples), ↑CRP (n=2 of 7 samples)	CT: ground-glass opacities (n=7), nodular morphology (n=6)	Interferon (n=9), lopinavir (n=6)	0
131	Zhu, L	Case series	China	10	9	5 (50%)	Fever (n=4), cough (n=3), headache (n=2), asymptomatic (n=4)	WBC, CRP and PCT normal in all children; ↑ALT (n=2)	CT: pneumonia (n=5)	Lopinavir/ritonavir (n=4), interferon (n=4), oseltamivir (n=1), antibiotics (n=1), oxygen (n=1), glucocorticoids and IVIG (n=0)	0

Abbreviations: ABG-arterial blood gas; ASA-aminosalicylate; ALT- alanine aminotransferase; AST-aspartate aminotransferase; BUN-blood urea nitrogen; BNP-brain natriuretic peptide; CBC-complete blood count; CK-creatinine kinase; CPAP-continuous positive airway pressure; Cr-creatinine; CRP-C-reactive protein; CT-computed tomography; CXR-chest radiograph; ESR-erythrocyte sedimentation rate; Hgb-hemoglobin; Ig-immunoglobulin; IL-interleukin; IVIG-intravenous immunoglobulin; LDH-lactate dehydrogenase; LFTs-liver function tests; LUS-lung ultrasound; NK-natural killer cell; NR-not reported; PCT-procalcitonin; Plts-platelets; PT-prothrombin time; PTT-partial thromboplastin time; RSV-respiratory syncytial virus; TNF-tumor necrosis factor. *One patient met our inclusion, but the publication was a case series.

Table 2

Patient characteristics, exposure status, and hospital stay.

	# Studies	# Patients	N (%)
Male gender	113	4640	2582 (55.6)
Mean age (years)	116	4517	8.9 ± 0.5
Exposure from family member	94	1360	1028 (75.6)
Travel to/lived-in high-risk area	84	962	689 (71.6)
NP/throat SARS-CoV-2 detection	89	787	681 (86.5)
Positive fecal viral shedding	31	321	67 (20.9)
Positive urine viral shedding	22	54	2 (3.7)
Length of hospital stay (days)	68	652	11.6 ± 0.3
Intensive care unit admission	88	3564	116 (3.3)

Continuous data presented as Mean ± SD. NP-nasopharyngeal.

Table 3

Underlying medical conditions and co-infection.

	# Studies	# Patients	N (%)
Underlying conditions	20	655	233 (35.6)
Immunosuppression			71 (30.5)
Respiratory			49 (21.0)
Cardiovascular			32 (13.7)
Medically complex/congenital malformations			25 (10.7)
Not reported			17 (7.3)
Hematologic			8 (3.8)
Neurologic			8 (3.4)
Obesity			8 (3.4)
Prematurity			5 (3.4)
Endocrine/metabolic			5 (2.1)
Renal			4 (1.7)
Gastrointestinal			1 (0.5)
Co-infections	35	1183	72 (5.6)
Bacterial			
Mycoplasma pneumoniae			42 (58.3)
Enterobacter sepsis			2 (2.8)
Streptococcus pneumoniae			1 (1.4)
Viral			
Influenza virus A/B			8 (11.1)
Respiratory syncytial virus			7 (9.7)
Cytomegalovirus			3 (4.2)
Epstein-Barr virus			3 (4.2)
Adenovirus			2 (2.8)
Human metapneumovirus			2 (2.8)
Human parainfluenza virus			2 (2.8)

Eleven patients (0.14%) met the CDC's criteria for MIS-C [7]. Compared to control ($n=14$), children with severe inflammation were more likely to present with dyspnea (72.7% vs 28.6%), vomiting (45.5% vs. 7.1%), and diarrhea (45.5% vs. 21.4%). White blood cell counts were comparable between the groups; however, patients with MIS-C have significant lymphopenia (11.1% vs. 41.8%). No difference was noted in platelets or liver function markers. Serum lactate dehydrogenase and D-dimer were higher in children with MIS-C ($p<0.05$, details provided in Table 7). Also, patients with MIS-C had lower expression of circulating CD16⁺CD56⁺ natural killer cells. Imaging findings and treatments were comparable in MIS-C and non-MIS-C patients.

Discussion

Over the last 6 months, there have been over 6.4 million worldwide cases of SARS-CoV-2 infection and our knowledge of the disease and its epidemiologic and clinical characteristics continue to evolve [4]. However, since it was first reported in Wuhan city in December 2019, most studies have focused on symptomatic adults. In the presence of this rapidly emerging, novel infection, identification of clinical and laboratory characteristics in the pediatric population is essential to guide clinical care, predict disease severity, and determine prognosis. In this context, we performed the largest and most

comprehensive systematic review of published studies involving pediatric patients with known COVID-19. Our systematic review summarized the clinical, laboratory and radiologic features of COVID-19 in neonates, children, and adolescents.

Our review also supports the findings by a recent systematic review by Castagnoli et al. [17] Their study included a total of 1,065 COVID-19 infected children and concluded that, by and large, the prognosis for children was excellent, demonstrated by only one death. Compared to that review and other COVID-19 pediatric systematic reviews, [18–21] this manuscript has several key advantages: (1) we summarize 131 studies that includes 7780 children from 26 different countries, (2) this report synthesizes underlying pediatric medical conditions and delineates bacterial and viral coinfections, (3) we quantitatively describe clinical symptoms and imaging findings, (4) herein, we conglomerate the mean and standard deviation of frequently used laboratory analytes in COVID-19 positive children, (5) our report presents antiviral therapies by specific agents, and (6) our systematic review offers a preliminary comparison of patients with/without MIS-C.

Although SARS-CoV-2 infection was first identified in China, the United States has now amassed the highest number of confirmed cases [18]. Calculations made on June 4th, 2020 from the COVID-19 Dashboard by the Center for

Systems Science and Engineering at Johns Hopkins University indicate that China has 4.5% of total confirmed COVID-19 cases compared to the United States [4]. As expected, the most common vector for childhood infection is close contact to an affected family member or residing in an area with a high population of cases. Our findings align with the results of an April 2020 report by Dong *et al*, in which there was a clear trend that the disease spread rapidly from a Chinese province to surrounding provinces and cities in children from December to February [22]. Furthermore, Qiu and colleagues studied 36 pediatric COVID-19 positive patients in which ten patients (28%) were asymptomatic latent cases identified secondary to an adult family member who was infected, symptomatic, or traveled to an endemic area [23]. This lends concern that children, who may be asymptomatic, may play a role in community transmission of the virus.

Table 4

Clinical symptoms and imaging

	# Studies	# Patients	N (%)
Clinical symptoms			
Asymptomatic	119	2367	456 (19.3)
Fever	119	2445	1446 (59.1)
Cough	119	2445	1367 (55.9)
Rhinorrhea, nasal congestion	119	2445	488 (20.0)
Myalgia, fatigue	119	2445	457 (18.7)
Sore throat	119	2445	446 (18.2)
Shortness of breath, dyspnea	119	2445	287 (11.7)
Abdominal pain, diarrhea	119	2445	159 (6.5)
Vomiting, nausea	119	2445	131 (5.4)
Headache, dizziness	119	2445	104 (4.3)
Pharyngeal erythema	119	2445	80 (3.3)
Decreased oral intake	119	2445	42 (1.7)
Rash	119	2445	6 (0.25)
Chest x-ray findings			
Normal	49	501	118 (23.6)
Patchy lesions	49	501	105 (21.0)
Ground-glass opacity	49	501	30 (6.0)
Consolidation	49	501	12 (2.4)
Computed Tomography (CT) findings			
Ground-glass opacity	67	1115	367 (32.9)
Normal	67	1115	211 (18.9)
Patchy lesions	67	1115	117 (10.5)
Consolidation	67	1115	72 (6.5)

Table 5
Laboratory values.

	# Studies	# Patients	Mean (SD)
Complete blood count			
Leukocytes ($10^3/\mu\text{L}$) (normal range 4.0-12.0)	63	811	7.1 (0.3)
Neutrophils (%) (normal range 54-62)	43	512	44.4 (2.7)
Lymphocytes (%) (normal range 25-33)	52	672	39.9 (2.0)
Hemoglobin (g/dL) (normal range 11.5-14.5)	35	211	12.9 (0.9)
Platelets ($10^3/\mu\text{L}$) (normal range 150-450)	38	115	272.5 (8.5)
Liver and renal function			
Creatinine (mg/dL) (normal range 0.22-0.59)	27	449	0.3 (0.0)
Aspartate aminotransferase (U/L) (normal range 15-50)	32	469	29.4 (2.2)
Alanine aminotransferase (U/L) (normal range 5-45)	35	656	19.5 (1.0)
Urea (mg/dL) (normal range 5-18)	12	227	4.6 (0.9)
Inflammatory markers			
C-reactive protein (mg/L) (male normal range 0.6-7.9) (female normal range 0.5-10.0)	45	643	9.4 (0.5)
D-dimer (mg/L)* (adult normal range <0.4)	16	285	0.7 (0.1)
Procalcitonin (ng/mL) (normal range ≤ 0.15 ng/mL)	29	259	0.25 (0.0)
Lactate dehydrogenase (U/L) (normal range 150-500)	25	404	276.6 (25.9)
Creatine kinase (U/L) (adult normal range 5-130)	25	193	197.9 (23.1)
Fibrinogen (mg/dL)* (normal range 220-440)	7	179	224.2 (1.3)
ESR (mm/h)* (normal range 0-20)	7	134	14.1 (3.4)
Interleukin-6 (pg/mL) (normal range ≤ 1.8)	9	92	26.1 (3.7)
Ferritin (ng/mL) (normal range 10-60)	3	22	51.6 (13.2)

Given that the mean (SD) in our pediatric population was 8.9 ± 0.5 years we provide the lowest to highest numbers presented in children with a similar age range when possible (data from Nelson Textbook of Pediatrics 2019). *Gregory's Pediatric Anesthesia 2012 5th edition.

† Mayo clinic laboratories.

Results from this systematic review echo findings describing milder symptoms in pediatric cases of SARS-CoV-2 infection [17,21]. For instance, the most common clinical manifestations we found were fever (59.1%), cough (55.9%), rhinorrhea (20.0%) and myalgia/fatigue (18.7%). Unlike adults, children rarely progressed to severe upper respiratory symptoms requiring intensive care unit admission [24,25]. Although transmission rates for SARS-CoV-2 are high, symptoms are less severe than SARS/Middle East Respiratory Syndrome (MERS) infection [26].

Serum inflammatory markers, specifically D-dimer, procalcitonin, creatine kinase, and interleukin-6, were consistently abnormal in the studies included in this review. Alterations to acute-phase infection-related biomarkers are corroborated in adult case series and meta-analyses [27,28]. However, we must take caution when interpreting these outcomes and await more robust, longitudinal laboratory analyses. Again, these blood analyses are non-specific and may merely represent a pro-inflammatory state induced by the virus [26].

In terms of imaging findings, we found that most patients had normal chest x-rays, a finding that is not surprising as most pediatric patients did not present with respiratory symptoms. Paralleling this review, a meta-analysis of CT features for COVID-19, showed that diffuse bilateral ground-glass opacities were the most common finding

TABLE 6
Treatments and complications

	# Studies	# Patients	N (%)
Treatments			
Interferon	66	614	252 (41.0)
Antibiotics	66	614	124 (20.2)
Remdesivir/unspecified antiviral	66	614	134 (21.8)
Herbs/home remedies/other	66	614	126 (20.5)
Lopinavir/ritonavir	66	614	71 (11.6)
Oseltamivir	66	614	53 (8.6)
Hydroxychloroquine	66	614	48 (7.8)
Glucocorticoids	66	614	25 (4.1)
Intravenous immunoglobulin	66	614	19 (3.1)
Arbidol	66	614	16 (2.6)
Ribavirin	66	614	13 (2.1)
Tocilizumab	66	614	9 (1.5)
Complications			
Death	131	7780	7 (0.09)
Mechanical ventilation	131	7780	42 (0.54)
Shock	131	7780	19 (0.24)
DIC	131	7780	9 (0.12)
Kidney failure	131	7780	9 (0.12)
Cardiac injury	131	7780	8 (0.10)
MIS-C	131	7780	11 (0.14)

at all stages of disease [29,30]. Despite these promising associations, it is important to consider that radiologic manifestations from various pathogens may have a similar impression and should be ruled out. Co-infections with other respiratory illnesses including influenza and mycoplasma were described in 72 patients. As elegantly described by Cox and colleagues, most fatalities from the 1918 influenza outbreak were secondary to bacterial infection [31]. Thus, future reports should not only describe coinfections but also detail pertinent negatives. At present, our study had a low rate of reporting the infectious workup (26.7) of patients. Illustrating the importance, one of two patients that died in the study by Shekerdemian *et al* was due to gram negative sepsis in a child with comorbidities who developed end organ failure [32].

Although most children have an uneventful course, a present concern is an inflammatory cascade in pediatric patients with COVID-19 [8,9]. Clinical presentation includes an unremitting high fever, and includes systemic signs such as rash, conjunctivitis, and/or gastrointestinal symptoms. The case series of eight children from London required respiratory assistance, whether it was oxygen support ($n=1$), noninvasive ventilation ($n=2$) or intubation and mechanical ventilation ($n=4$) [8]. One patient was so ill that he required mechanical ventilation and extracorporeal membrane oxygenation. In addition, all required vasopressor support and demonstrated elevated levels of ferritin, D-dimers, troponin, procalcitonin, and C-reactive protein (CRP). Additionally, cardiac imaging showed ventricular dysfunction in five children. In another article, Italian investigators describe ten patients with MIS-C. Correspondingly, they describe patients manifesting with fever, diarrhea ($n=6$), and abnormal echocardiograms ($n=6$). Laboratory specifics showed elevated CRP, lymphopenia, thrombocytopenia, and elevated ferritin levels [9].

We found evidence of MIS-C features in 11 children who also presented with fever ($n=11$), dyspnea ($n=8$), and diarrhea ($n=6$). According to Riphagen and Verdoni, lymphopenia was marked in our cohort of patients, as well as increased levels of lactate dehydrogenase, CRP and D-dimer [8,9]. Despite low numbers we did observe an interesting lower level of CD16⁺CD56⁺ natural killer (NK) cells in patients with MIS-C. Both lymphopenia and a reduced number/activity of NK cells in adults has correlated with a more severe COVID-19 disease progression [33-36].

Little is known about the perinatal aspects of COVID-19, and there have been several reported cases of neonatal infection, suggesting a possible perinatal or vertical transmission during pregnancy [37]. However, in a report by Chen *et al.*, all nine neonates born to COVID-

Table 7
Comparison between covid-19 children with and without multisystem inflammatory syndrome in children (MIS-C).

	COVID-19	MIS-C	
Number of patients	14	11	NA
Age, years	7.5 (1.8, 13.7)	1.1 (0.7, 12.0)	0.15
Gender, male	10 (71.4%)	6 (54.5%)	0.43
Clinical characteristics			
Fever	10 (71.4%)	10 (90.9%)	0.34
Cough	8 (57.1%)	6 (54.5%)	1.00
Dyspnea	4 (28.6%)	8 (72.7%)	0.04
Vomiting	1 (7.1%)	5 (45.5%)	0.02
Diarrhea	3 (21.4%)	5 (45.5%)	0.02
Underlying medical conditions	1 (7.1%)	3 (27.3%)	0.14
Laboratory parameters			
White blood cell count ($10^3/\mu\text{L}$)	7.8 (4.6, 8.3)	9.0 (5.0, 11.3)	0.23
Neutrophils	49.4% (31.4, 65.4)	58.9% (55.3, 65)	0.25
Lymphocytes	41.8% (22.4, 53.8)	11.1% (5.9, 25.7)	<0.01
Hemoglobin (g/dL)	12.6 (2.3)	12.1 (2.4)	0.66
Platelets ($10^3/\mu\text{L}$)	250 (173, 301)	193 (107, 251)	0.22
Aspartate aminotransferase (U/L)	23.0 (17.0, 37.0)	30.0 (18.8, 36.0)	0.96
Alanine aminotransferase (U/L)	17.0 (11.0, 31.0)	26.6 (12.0, 55.0)	0.45
Creatine kinase (U/L)	77 (71, 113)	106 (62, 380)	0.45
Lactate dehydrogenase (U/L)	217 (203, 367)	459 (380, 609)	<0.01
C-reactive protein (mg/L)	1.1 (0.5, 9.9)	13.3 (1, 57.9)	0.07
Interleukin-2 (pg/mL)*	2.6 (1.0)	1.4 (0.3)	0.06
Interleukin-4 (pg/mL)*	4.4 (1.5)	2.8 (0.8)	0.11
Interleukin-6 (pg/mL)*	14.3 (4.8, 9.0)	118 (4.7, 25.4)	0.81
Interleukin-10 (pg/mL)*	6.9 (4.8, 9.0)	15.1 (4.7, 25)	0.56
Tumor necrosis alpha (pg/mL)*	4.3 (3.2, 5.4)	8.4 (1.4, 4.5)	0.46
Interferon gamma (pg/mL)*	8.6 (5.9, 15)	3.1 (1.5, 21)	0.25
CD16+CD56+*	11.0% (5.1)	4.2% (2.2)	0.03
CD3+*	72.0% (14.4)	60.0% (12.9)	0.23
CD4+*	29.4% (3.8)	34.7% (10.1)	0.36
D-dimer (mg/L)*	0.3 (0.3, 0.5)	40.3 (3.1, 11806)	<0.01
Procalcitonin (ng/mL)	0.09 (0.09, 0.13)	0.11 (0.04, 0.83)	0.72
Imaging findings and treatment			
Normal chest x-ray	7 (50%)	0 (0%)	0.15
Normal lung computed tomography	5 (35.7%)	0 (0%)	0.47
Interferon	5 (35.7%)	5 (45.5%)	0.23
Oseltamivir	3 (21.4%)	5 (45.5%)	1.00
Glucocorticoids	2 (14.3%)	6 (54.5%)	0.13
Intravenous immunoglobulin	3 (21.4%)	5 (45.5%)	1.00
Virazole	3 (21.4%)	4 (36.4%)	1.00
Tocilizumab	0 (0%)	2 (18.2%)	0.49

Data are presented as mean (SD) or median (IQR). Student's t test, Wilcoxon rank sum, or Fisher's exact was conducted as appropriate. * denotes limited data was in at least one group (D-dimer in MIS-C=3; Interleukins and CDs had 4 in non-MIS-C group vs. 4-5 in MIS-C).

19 positive mothers tested negative for the virus after cesarean delivery [38]. In another study by Zhang *et al.*, 10 neonates from COVID-19 positive mother all tested negative for the infection [39]. Moreover, this is further supported by analysis of breast milk and placental pathologic specimens from COVID-19 positive mothers, which have returned negative for the virus [40,41]. Lastly, vertical transmission was not observed with either SARS-CoV-1 or in MERS-CoV; [41] therefore, it is unlikely that maternal vertical transmission during third trimester occurs, or is likely very rare. However, from the limited data published, we cannot determine the consequences of SARS-CoV-2 infection in early pregnancy and if it can be transmitted to the fetus and hinder organ development, malformations, growth abnormalities, or even lead to premature labor or spontaneous abortions [42,43]. Also, Dong *et al* communicated an alarming finding in which the proportion of severe and critical cases were higher in neonates when compared to the >16-year-old age group (10.6% vs. 3.0%) [44]. As a community, we must stay vigilant, practice social distancing, hand wash frequently, and be especially careful with our children who are at potentially higher risk for critical disease (e.g. multiple comorbidities, weakened immune systems, etc.).

There are several limitations to this review. First, many of the included studies were case reports or cases with low patient numbers.

Second, the level of evidence for all the studies was low. Next, we unified the laboratory data to mean and standard deviation. There are inherent issues when using averages including the impact of outliers. We did not include suspected cases, which would allow for a direct comparison of symptoms, labs, imaging, and outcome data. Of concern, many of the studies were incomplete and did not include a comprehensive picture of the patients. Future studies should not generalize data ("CBC was normal"), or categorize laboratory values (i.e., number of patients with elevated CRP), or group therapies (i.e., patient received "antiviral therapy"), or display aggregate data between adults and children. If feasible, divide the symptoms, laboratory markers, and imaging characteristics by children vs. adults. A better understanding of COVID-19 requires access to data, even if it is provided in the appendix or supplementary section of the article. In this way, we will be able to identify the best biomarkers that can stratify disease severity and potential short- and long-term outcomes. Another limitation, is that we had a small number of patients that fit the criteria for MIS-C. Reasons for the small number of patients includes a lack of reporting all of the signs, symptoms, and laboratory markers necessary to make the diagnosis (especially duration of fever). Missing information for laboratory markers (D-dimer, interleukins, and CD%) hinders our preliminary findings. Lastly, the

literature focusing on COVID-19 is very dynamic and growing rapidly and we expect the rates, especially for MIS-C, of our outcomes to change.

Contributors

Ansel Hoang—literature search, study design, data collection, data analysis, data interpretation, manuscript writing, risk of bias, tables. Kevin Chorath—literature search, study design, data collection, data interpretation, manuscript writing, risk of bias. Axel Moreira—literature search, study design, data collection, manuscript writing, data interpretation, risk of bias. Mary Evans—data collection, verifying data integrity, risk of bias. Finn Burmeister—Morton—data collection, verifying data integrity. Fiona Burmeister—data collection, verifying data integrity, risk of bias. Rija Naqvi—data collection, verifying data integrity, risk of bias. Matthew Petershack—data collection, risk of bias. Alvaro Moreira—literature search, study design, data collection, data analysis, data interpretation, manuscript writing, figure, tables, oversight.

Declaration of Competing Interest

None.

Acknowledgments

Funding sources: Parker B. Francis; Pilot grant 2R25-HL126140. Funding agencies had no role in the writing of the manuscript or the decision to submit.

Supplementary materials

Supplementary material associated with this article can be found in the online version at doi:[10.1016/j.eclinm.2020.100433](https://doi.org/10.1016/j.eclinm.2020.100433).

References

- [1] Du Z, Wang L, Cauchemez S, et al. Risk for transportation of coronavirus disease from Wuhan to other cities in china. *Emerg Infect Dis J* 2020;26:1049. doi: [10.3201/eid2605.200146](https://doi.org/10.3201/eid2605.200146).
- [2] Gao Q, Hu Y, dai Sr Z, Wu J, Xiao F, Wang J. The epidemiological characteristics of an outbreak of 2019 novel coronavirus diseases (COVID-19) in Jingmen, Hubei, China 2020;10 March. doi: [10.1101/2020.03.07.20031393](https://doi.org/10.1101/2020.03.07.20031393).
- [3] Cucinotta D, Vanelli M. WHO declares covid-19 a pandemic. *Acta Biomed* 2020;91:157–60. doi: [10.23750/abm.v91i1.9397](https://doi.org/10.23750/abm.v91i1.9397).
- [4] Johns Hopkins University and Medicine. Coronavirus resource center. [Coronavirus resource center](https://coronavirus.jhu.edu/map.html) (accessed June 3, 2020).
- [5] WHO. Coronavirus disease 2019 (COVID-19): situation report-28, 2020. https://www.who.int/docs/default-source/coronavirus/situation-reports/20200217-sitrep-28-covid-19.pdf?sfvrsn=a19cf2ad_2 (accessed May 13, 2020).
- [6] Wang E, Brar K. COVID-19 in children: an epidemiology study from China. *J Allergy Clin Immunol Pract* 2020 April 23. doi: [10.1016/j.jaip.2020.04.024](https://doi.org/10.1016/j.jaip.2020.04.024).
- [7] Centers for Disease Control and Prevention. Resources for Emergency Health Professionals. Health Alert Netw 2020 <https://emergency.cdc.gov/han/2020/han00432.asp> (accessed June 3).
- [8] Riphagen S, Gomez X, Gonzales-Martinez C, Wilkinson N, Theocharis P. Hyperinflammatory shock in children during COVID-19 pandemic *Lancet* 2020; May 7. DOI: [10.1016/S0140-6736\(20\)31094-1](https://doi.org/10.1016/S0140-6736(20)31094-1).
- [9] Verdoni L, Mazza A, Geronzi A, et al. An outbreak of severe Kawasaki-like disease at the Italian epicentre of the SARS-CoV-2 epidemic: an observational cohort study. *Lancet* 2020 May 13. doi: [10.1016/S0140-6736\(20\)31103-X](https://doi.org/10.1016/S0140-6736(20)31103-X).
- [10] National Institutes of Health (2014). National Heart, Lung, and Blood Institute. Quality assessment tool for observational cohort and cross-sectional studies. [Nhlbi.nih.gov/health-topics/study-quality-assessment-tools](https://www.nhlbi.nih.gov/health-topics/study-quality-assessment-tools) June 3, 2020 (accessed).
- [11] Farrah K, Young K, Tunis M, Zhao L. Risk of bias tools in systematic reviews of health interventions: an analysis of PROSPERO-registered protocols. *Syst Rev* 2019;1:280.
- [12] Sackett DL. Rules of evidence and clinical recommendations on the use of antithrombotic agents. *Chest* 1989;95:2S–4S.
- [13] Wan X, Wang W, Liu J, Tong T. Estimating the sample mean and standard deviation from the sample size, median, range and/or interquartile range. *BMC Med Res Methodol* 2014;14:135. doi: [10.1186/1471-2288-14-135](https://doi.org/10.1186/1471-2288-14-135).
- [14] Bialek S, Gierke R, Hughes M, McNamara LA, Pilishvili T, Skoff T. Coronavirus Disease 2019 in Children — United States, 2020. *MMWR Morb Mortal Wkly Rep* 2020 February 12–April 2; 69:422–426. DOI: [10.15585/mmwr.mm6914e4](https://doi.org/10.15585/mmwr.mm6914e4).
- [15] Wang J, Wang D, Chen GC, Tao XW, Zeng LK. SARS-CoV-2 infection with gastrointestinal symptoms as the first manifestation in a neonate. *Zhongguo Dang Dai Er Ke Za Zhi* 2020;22:211–4.
- [16] Zeng L, Xia S, Yuan W, et al. Neonatal early-onset infection with SARS-CoV-2 in 33 neonates born to mothers with COVID-19 in Wuhan, China. *JAMA Pediatr* 2020 March 26. doi: [10.1001/jamapediatrics.2020.0878](https://doi.org/10.1001/jamapediatrics.2020.0878).
- [17] Castagnoli R, Votto M, Licari A, et al. Severe acute respiratory syndrome coronavirus 2 (SARS-CoV-2) infection in children and adolescents: a systematic review. *JAMA Pediatr* 2020 April 22. doi: [10.1001/jamapediatrics.2020.1467](https://doi.org/10.1001/jamapediatrics.2020.1467).
- [18] Souza T, Nadal J, Nogueira R, Pereira R, Brandao M. Clinical manifestations of children with COVID-19: a systematic review. *Pediatr Pulmonol* 2020 June 3. doi: [10.1002/ppul.24885](https://doi.org/10.1002/ppul.24885).
- [19] Panahi L, Amir M, Pouy S. Clinical characteristics of COVID-19 infection in newborns and pediatrics: a systematic review. *Arch Acad Emerg Med* 2020;18:e50.
- [20] Mustafa N, Selim L. Characterisation of COVID-19 pandemic in paediatric age group: a systematic review and meta-analysis. *J Clin Virol* 2020 May 8. doi: [10.1016/j.jcv.2020.104395](https://doi.org/10.1016/j.jcv.2020.104395).
- [21] Ludvigsson J. Systematic review of COVID-19 in children shows milder cases and a better prognosis than adults. *Acta Paediatr* 2020;109:1088–95.
- [22] Dong Y, Mo X, Hu Y, et al. Epidemiological characteristics of 2143 pediatric patients with 2019 coronavirus disease in china. *Pediatrics* 2020 March 17. doi: [10.1542/peds.2020-0702](https://doi.org/10.1542/peds.2020-0702).
- [23] Qiu H, Wu J, Hong L, Luo Y, Song Q, Chen D. Clinical and epidemiological features of 36 children with coronavirus disease 2019 (COVID-19) in Zhejiang, China. *Observat Cohort Study Lancet Infect Dis* 2020 March 25. doi: [10.1016/S1473-3099\(20\)30198-5](https://doi.org/10.1016/S1473-3099(20)30198-5).
- [24] Rodriguez-Morales AJ, Cardona-Ospina JA, Gutierrez-Ocampo E, et al. Clinical, laboratory and imaging features of COVID-19: A systematic review and meta-analysis. *Travel Med Infect Dis* 2020 March 13. doi: [10.1016/j.tmaid.2020.101623](https://doi.org/10.1016/j.tmaid.2020.101623).
- [25] Huang C, Wang Y, Li X, et al. Clinical features of patients infected with 2019 novel coronavirus in Wuhan, China. *Lancet* 2020;395:497–506. doi: [10.1016/S0140-6736\(20\)30183-5](https://doi.org/10.1016/S0140-6736(20)30183-5).
- [26] Thabet F, Chehab M, Bafaqih H, Almohaimeed S. Middle east respiratory syndrome coronavirus in children. *Saudi Med J* 2015;36:484–6.
- [27] Aziz M, Fatima R, Assaly R. Elevated interleukin-6 and severe COVID-19: a meta-analysis. *J Med Virol* 2020 April 28. doi: [10.1002/jmv.25948](https://doi.org/10.1002/jmv.25948).
- [28] Zhu J, Ji P, Pang J, et al. Clinical characteristics of 3,062 COVID-19 patients: a meta-analysis. *J Med Virol* 2020 April 15. doi: [10.1002/jmv.25884](https://doi.org/10.1002/jmv.25884).
- [29] Xia W, Shao J, Guo Y, Peng X, Li Z, Hu D. Clinical and CT features in pediatric patients with COVID-19 infection: Different points from adults. *Pediatr Pulmonol* 2020;55:1169–74. doi: [10.1002/ppul.24718](https://doi.org/10.1002/ppul.24718).
- [30] Kumar-Venugopal V, Mahajan V, Rajan S, et al. A systematic meta-analysis of CT features of covid-19: lessons from radiology, 2020; April 7. DOI: [10.1101/2020.04.04.20052241](https://doi.org/10.1101/2020.04.04.20052241).
- [31] Cox M, Loman N, Bogaert D, O'Grady J. Co-infections: potentially lethal and unexplored in COVID19. *Lancet* 2020 April 24. DOI: [10.1016/S2666-5247\(20\)30009-4](https://doi.org/10.1016/S2666-5247(20)30009-4).
- [32] Shekerdemian L, Mahmood N, Wolfe K, et al. Characteristics and outcomes of children with coronavirus disease 2019 (COVID-19) infection admitted to US and Canadian pediatric intensive care units. *JAMA Pediatr*; May 11. DOI: [10.1001/jamapediatrics.2020.1948](https://doi.org/10.1001/jamapediatrics.2020.1948).
- [33] L Antoniolli, Fornai M, Pellegrini C, Blandizzi C. NKG2A and COVID-19: another brick in the wall. *Cell Mol Immunol* 2020;17:672–4.
- [34] Vabret N, Britton G, Gruber C, et al. Immunology of COVID-19: current state of the science. *Immunity* 2020 March 13. doi: [10.1016/j.immuni.2020.05.002](https://doi.org/10.1016/j.immuni.2020.05.002).
- [35] Tan L. Lymphopenia predicts disease severity of COVID-19: a descriptive and predictive study. *Signal Transduct Target Ther* 2020 April 29. doi: [10.1038/s41392-020-0159-1](https://doi.org/10.1038/s41392-020-0159-1).
- [36] Huang G, Kovalic AJ, Graber CJ. Prognostic value of leukocytosis and lymphopenia for coronavirus disease severity. *Emerg Infect Dis* 2020 May 8. doi: [10.3201/edi2608.201160](https://doi.org/10.3201/edi2608.201160).
- [37] Dong L, Tian J, He S, et al. Possible vertical transmission of sars-cov-2 from an infected mother to her newborn. *JAMA* 2020 March 26. doi: [10.1001/jama.2020.4621](https://doi.org/10.1001/jama.2020.4621).
- [38] Chen H, Guo J, Wang C, et al. Clinical characteristics, and intrauterine vertical transmission potential of COVID-19 infection in nine pregnant women: a retrospective review of medical records. *Lancet* 2020;395:809–15. doi: [10.1016/S0140-6736\(20\)30360-3](https://doi.org/10.1016/S0140-6736(20)30360-3).
- [39] Zhang L, Jiang Y, Wei M, et al. [Analysis of the pregnancy outcomes in pregnant women with COVID-19 in Hubei Province]. *Zhonghua Fu Chan Ke Za Zhi* 2020;55: E009. doi: [10.3760/cma.jcn112141-20200218-00111](https://doi.org/10.3760/cma.jcn112141-20200218-00111).
- [40] Zheng F, Liao C, Fan Q, et al. Clinical characteristics of children with coronavirus disease 2019 in Hubei, China. *Curr Med Sci* 2020 March 24. doi: [10.1007/s11596-020-2172-6](https://doi.org/10.1007/s11596-020-2172-6).
- [41] Chen S, Huang B, Luo DJ, et al. [Pregnant women with new coronavirus infection: a clinical characteristics and placental pathological analysis of three cases]. *Zhonghua bing li xue za zhi* 2020;49:E005. doi: [10.3760/cma.jcn112151-20200225-00138](https://doi.org/10.3760/cma.jcn112151-20200225-00138).
- [42] Rasmussen SA, Smulian JC, Lednický JA, Wen TS, Jamieson DJ. Coronavirus disease 2019 (COVID-19) and pregnancy: what obstetricians need to know. *Am J Obstet Gynecol* 2020 February 24. doi: [10.1016/j.ajog.2020.02.017](https://doi.org/10.1016/j.ajog.2020.02.017).
- [43] Mimouni F, Lakshminrusimha S, Pearlman SA, Raju T, Gallagher PG, Mendlovic J. Perinatal aspects on the covid-19 pandemic: a practical resource for perinatal-neonatal specialists. *J Perinatol* 2020;40:820–6. doi: [10.1038/s41372-020-0665-6](https://doi.org/10.1038/s41372-020-0665-6).
- [44] Dong Y, X Mo, Hu Y, et al. Epidemiology of COVID-19 among children in China. *Pediatrics* 2020 March 13. doi: [10.1542/peds.2020-0702](https://doi.org/10.1542/peds.2020-0702).